

Visual impairment in children with congenital Zika syndrome



Liana O. Ventura, MD, PhD,^{a,b} Camila V. Ventura, MD,^{a,b,c} Linda Lawrence, MD,^d Vanessa van der Linden, MD, Msc,^e Ana van der Linden, MD,^f Adriana L. Gois, MD,^{a,b} Milena M. Cavalcanti, MD,^{a,e} Eveline A. Barros, MD,^{a,b} Natalia C. Dias, MD,^a Audina M. Berrocal, MD,^c and Marilyn T. Miller, MD^g

PURPOSE	To describe the visual impairment associated with ocular and neurological abnormalities in a cohort of children with congenital Zika syndrome (CZS).
METHODS	This cross-sectional study included infants with microcephaly born in Pernambuco, Brazil, from May to December 2015. Immunoglobulin M antibody capture enzyme-linked immunosorbent assay for the Zika virus on the cerebrospinal fluid samples was positive for all infants. Clinical evaluation consisted of comprehensive ophthalmologic examination including visual acuity, visual function assessment, visual developmental milestone, neurologic examination, and neuroimaging.
RESULTS	A total of 32 infants (18 males [56%]) were included. Mean age at examination was 5.7 ± 0.9 months (range, 4-7 months). Visual function and visual developmental milestone could not be tested in 1 child (3%). Visual impairment was detected in 32 infants (100%). Retinal and/or optic nerve findings were observed in 14 patients (44%). There was no statistical difference between the patients with ocular findings and those without ($P = 0.180$). All patients (100%) demonstrated neurological and neuroimaging abnormalities; 3 (9%) presented with late-onset of microcephaly.
CONCLUSIONS	Children with CZS demonstrated visual impairment regardless of retina and/or optic nerve abnormalities. This finding suggests that cortical/cerebral visual impairment may be the most common cause of blindness identified in children with CZS. (J AAPOS 2017;21: 295-299)



The Zika virus (ZIKV) infection has been rapidly expanding throughout the world, with the northeastern part of Brazil being the major epicenter of the virus.^{1,2} On November 2016 the World Health Organization reported 73 countries and territories with active ZIKV transmission since Brazil confirmed an outbreak in May 2015.² Despite ZIKV infection often being mild or

even unrecognized, the exposure to the virus during pregnancy can lead to devastating effects on the developing fetus.^{1,3}

Congenital Zika syndrome (CZS) is the term used by many authors to describe the distinctive phenotype of babies infected with ZIKV in utero.³ The broad spectrum of systemic findings in CZS include neurological, ocular, hearing, and skeletal abnormalities.³⁻⁹ Although the neurological abnormalities are considered the hallmark of CZS, ocular findings have also been identified as an important component of the syndrome.^{3,4,9,10}

Ocular abnormalities related to the vertical transmission of ZIKV were first described by Ventura and colleagues⁷ in January 2016. Subsequent studies have shown that, although anterior segment findings and structural malformations such as microphthalmia can be found in CZS, ZIKV most commonly affects the posterior segment of the eye.⁷⁻¹¹ These findings include retinal pigmentary changes, sharply demarcated chorioretinal atrophy, vasculature changes, optic nerve hypoplasia, pallor, and increased cup:disk ratio.⁷⁻¹¹ The broad spectrum of ocular findings in CZS have been described; however, previous studies have not addressed its direct effect on visual acuity and visual function. The purpose of the current study was to evaluate visual impairment in babies

See accompanying editorial on page 259.

Author affiliations: ^aAltino Ventura Foundation (FAV), Recife, PE, Brazil; ^bDepartment of Ophthalmology, HOPE Eye Hospital, Recife, PE, Brazil; ^cDepartment of Ophthalmology, Bascom Palmer Eye Institute, Miller School of Medicine, University of Miami, Miami, Florida; ^dPrivate Ophthalmology practice, Salina, Kansas; ^eDepartment of Pediatric Neurology, Disabled Children's Assistance Association (AACD), Recife, PE, Brazil; ^fDepartment of Pediatric Neurology, Materno Infantil Institute of Pernambuco (IMIP Hospital), Recife, PE, Brazil; ^gDepartment of Ophthalmology and Visual Sciences, University of Illinois, Chicago, Illinois

Submitted November 25, 2016.

Revision accepted March 22, 2017.

Published online April 24, 2017.

Correspondence: Linda Lawrence, MD, 1410 East Iron #6, Salina, KS 67401 (email: lmllawrencemd@gmail.com).

Copyright © 2017, American Association for Pediatric Ophthalmology and Strabismus. Published by Elsevier Inc. All rights reserved.

1091-8531/\$36.00

<http://dx.doi.org/10.1016/j.jaaapos.2017.04.003>

with CZS and to correlate it with ocular and neurological findings.

Subjects and Methods

The Institutional Review Board of the Altino Ventura Foundation (FAV) approved this cross-sectional study, which followed the tenets of the Declaration of Helsinki. The parents of the infants provided written informed consent before their children were enrolled. The study was conducted at the FAV's Rehabilitation Center, Recife, Pernambuco, Brazil.

Comprehensive ophthalmic evaluation was performed for each infant by a pediatric ophthalmologist and an ophthalmologist specialized in vitreoretinal disease. The same pediatric ophthalmologist and another with experience in pediatric low-vision rehabilitation assessed the visual function of the infants. Three pediatric neurologists evaluated the patients' neurodevelopment and reviewed brain neuroimaging.

Infants with neurological findings and neuroimaging abnormalities under investigation for CZS at the Hospital Barão de Lucena and the Disabled Children's Assistance Association, Recife, Pernambuco, Brazil, were included. Infants born from May to December 2015 in the state of Pernambuco, Brazil, with any neuroimaging or neurological abnormalities detected at birth and positive IgM for ZIKV infection using the antibody-capture enzyme-linked immunosorbent assay (MAC-ELISA) method on cerebrospinal fluid (CSF) were included. The CSF testing used in this study to confirm ZIKV infection has been described elsewhere.⁹ Infants with positive serology for other congenital infection, such as toxoplasmosis, rubella, cytomegalovirus (CMV), syphilis, herpes, and human immunodeficiency virus (HIV), were excluded.

Mothers were interviewed individually by a pediatric ophthalmologist using the same standardized questionnaire used in a previous publication.⁹ The timing of signs and/or symptoms that appeared during pregnancy was specifically asked to each mother.

Babies were defined as preterm if born before completing 37 weeks of gestation and at term when born between 37 and 42 weeks. The semesters were defined as follows: first trimester, up to the end of the 13th week; second trimester, from the 14th to the 27th week; and third trimester, from the 28th week onward.

Ophthalmologic Assessment

All infants received a comprehensive ophthalmic examination, comprising evaluation of visual acuity, pupillary examination, ocular motility testing, accommodative reflexes (estimated by dynamic retinoscopy), cycloplegic refraction, and indirect ophthalmoscopy. Visual function and visual developmental milestones were also evaluated.

Monocular and binocular visual acuity was assessed in infants using the Teller Acuity Cards II (TAC; Stereo Optical Co Inc, Chicago, IL) and was recorded in cycles per cm (cy/cm). TAC was measured according to the manufacturer's handbook at 38 cm for all patients, including 4 patients already 7 months old (cases 2, 7, 20, and 29), because they could not see at 55 cm.¹²

Visual acuity was considered normal when the adequate and expected vision for the corrected chronological age of the child was verified (within the 95% normative tolerance limits) and abnormal when below normative tolerance limit.¹³

Strabismus was evaluated and classified according to the type and measured using Krimsky test at near. Variable strabismus in infants was identified as strabismus that fluctuated between esotropia and exotropia under standard examination conditions. The character of the nystagmus was not noted in this study, only presence or absence.

Visual function assessment included light perception, response to the human face, shift of gaze for cortical function evaluation (evaluates whether purposeful saccades between two targets are intact), and the Hiding Heidi contrast test, with response considered normal if 5% contrast paddle was seen at 30 cm.

The visual developmental milestones measures included eye contact at 8 weeks, social smile at 3 months, regarding hands at 3 months, and goal directed reach, moving to reach, and bringing hands to midline at 5-6 months.

Visual function and visual developmental milestone assessment was developed based on the *Parents and Their Infants with Visual Impairments (PAIVI)*.^{14,15} For the current study, visual impairment was defined as either a measured visual acuity below the TAC test standard normal, and/or failure to achieve one or more of the visual function tests or visual developmental milestones.

Cycloplegic refractions were performed by static retinoscopy 30 minutes after instillation of 1 drop of 0.5% cyclopentolate hydrochloride and 1 drop of 0.5% tropicamide in each eye. A lower dose than usual for cycloplegia was used because of the infants' neurological fragility. Hyperopia was defined as a spherical correction of $\geq +2.00$ D; myopia, as a spherical correction of ≥ -1.00 D; and astigmatism, as a cylindrical correction of ≥ 0.75 D.

Bilateral retinal imaging was performed in all babies after dilation of the pupil, using a wide-angle digital fundus camera (RetCam, Clarity, Pleasanton, CA).

Infant's retina and optic nerve characteristics at baseline here reported have been described in detail previously and are only summarized here.⁷⁻¹¹ Increased disk cupping was considered when the cup:disk ratio was >0.5 and was reported simply as a clinical observation. Because glaucoma evaluation was not the goal of the present study, intraocular pressure was not measured. However, no infant presented with typical primary congenital glaucoma symptoms nor clinical signs.

The diagnosis of optic nerve hypoplasia was made during ophthalmoscopic examination and was based on the typical appearance of small optic nerve, often associated to the double ring sign.

Neurologic Assessment

Pediatric neurologists performed the neurodevelopmental clinical evaluation. All patients underwent neuroimaging with brain computerized tomography (CT) without contrast. Microcephaly was defined as an occipitofrontal head circumference (OFC) below the third centile or more than 2 standard deviations below the mean for gestational age and sex.^{16,17}

Statistical Analysis

All statistical analyses were carried out using SPSS version 16.0 (version 16.0; SPSS Inc, Chicago, IL). Continuous data were recorded as mean with standard deviation as well as range. The Fisher exact test was used to determine whether there was any significant association between the abnormal TAC results and the fundus abnormalities identified. $P < 0.05$ was considered significant.

Results

A total of 32 infants (18 males [56%]) were included. Mother's mean age at delivery was 26.3 ± 7.3 years old (range, 14-41 years). Twenty-six mothers (81%) reported symptoms or signs compatible with ZIKV infection during pregnancy such as rash, fever, and arthralgia. Thirteen mothers (50%) reported symptoms in the first trimester, 9 (35%) in the second trimester, and 3 (12%) in the third trimester; 1 (4%) could not inform. See [eSupplement 1](#) (available at [jaapos.org](#)).

Mean gestational age at birth was 37.9 ± 2.4 weeks (range, 31-41 weeks): 26 infants (81%) were term; 6 (19%), preterm. At birth, the mean OFC was 28.7 ± 1.9 cm (range, 25-33 cm): microcephaly was seen in 29 infants (91%). The mean birth weight was 2627 ± 530 g (range, 1460-3900 g).

Mean age of testing at the ophthalmological examination was 5.7 ± 0.9 months (range, 4.0-7.0 months). The binocular TAC test was abnormal in 22 of the 30 testable infants (73%) and monocular in 47 of 60 eyes (78%). The direct (afferent) pupillary reflex was abnormal in 3 infants (9%) and could not be evaluated in 1 infant (3%). Ocular alignment at near revealed exotropia in 11 patients (34%) and esotropia in 10 (31%); variable strabismus was evident in 3 patients (9%). Nystagmus was observed in 9 infants (28%). Out of the 14 patients that could have dynamic retinoscopy assessed, 5 patients (36%) showed diminished accommodation. As for the refractive errors detected, astigmatism was found in 29 of the 64 eyes (45%), hyperopia in 26 eyes (41%), and myopia in 5 eyes (8%). See [eTable 1](#).

Visual function and visual developmental milestones were assessed in 31 infants; 1 child (case 11) was not testable at the time of the evaluation. All infants manifested light perception and presented abnormality in at least one of the visual function or visual developmental milestone test. Twenty-two children (71%) presented at least one visual function alteration, and 4 (13%) did not respond to any visual function test. Twenty infants (65%) did not respond to the Hiding Heidi at 5% contrast or less at 10-12 inches (25-30 cm). Shift of gaze was abnormal in 13 children (42%), and 4 (13%) were not testable due to poor visual attention ([eTable 2](#)).

The visual developmental milestones evaluation detected that 30 of 31 infants (97%) were not able to perform at least one of the milestones expected for their age. Eight babies (26%) could not make eye contact, and 16 (52%) had no social smile. For the 3-month milestone, 26 infants (83.9%) were not able to perform regard for hands. For the

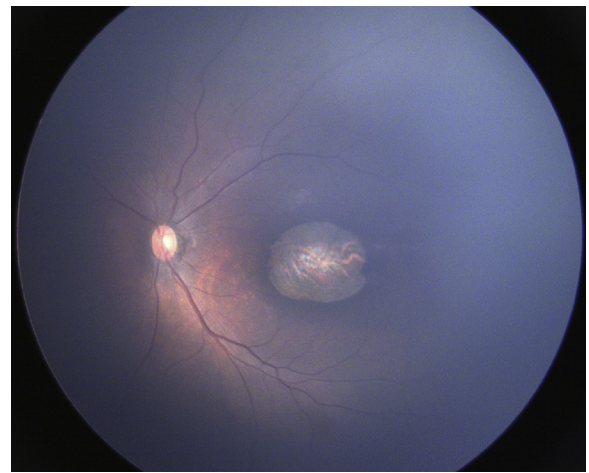


FIG 1. Wide-angle fundus image (RetCam) of the left eye of a child with congenital Zika syndrome showing large chorioretinal scar in the macular region.

5-6 month milestones, 17 of 27 infants (63%) could not perform goal directed reach, 20 (74%) did not use vision to move toward reaching, and 25 (93%) did not meet the developmental milestone of bringing hands to the midline. For 2 children >7 months' adjusted age, regard to facial features/expressions was observed.

Anterior segment examination was normal in all infants. Fundus findings were detected in 22 eyes (34%) of 14 patients (44%). See [Figure 1](#). When abnormal TAC results were analyzed according to the presence or absence of fundus findings, no statistical difference was found ($P = 0.180$). Retinal abnormalities were identified in 18/64 eyes (28%) and optic nerve abnormalities in 11 of 64 eyes (17%). Optic nerve findings included optic nerve hypoplasia in 5 eyes (8%), pallor in 5 eyes (8%), and increased cup:disk ratio in 6 eyes (9%). The observed macular abnormalities included, chorioretinal scars in 11 eyes (17%), pigment mottling in 9 eyes (14%). Bilateral hypopigmented lesions in the macular region were present in 1 patient (3%). Retinal vessels attenuation was seen in 2 eyes (3%) and straightening retinal vessels in 2 eyes (3%) ([eTable 3](#)).

The mean age at the neurological examination was 5.7 ± 0.9 months (range, 4.0-7.0 months). At the time of neurological assessment, all 32 infants presented with microcephaly (mean OFC, 35.3 ± 2.2 cm; range, 31.0-40.0 cm) and demonstrated neurological abnormalities. Seizure disorder was previously detected and being managed in 22 infants (69%). Of these 22, all presented visual impairment, and 9 (41%) presented with fundus findings. All infants had some degree of hypertonia; 31 infants (97%) had pyramidal and extrapyramidal signs with dystonic movement. One infant (case 19) had spastic hemiparesis. Exacerbated primitive reflexes were seen in 30 infants (94%) See [eSupplement 2](#) (available at [jaapos.org](#)).

All 32 children underwent CT scanning; 11 (34%) also underwent MRI scanning. Brain calcifications were present in 31 infants (97%) and located at the cortical and

subcortical white matter junction in 29 infants (91%). Cerebellar or brainstem hypoplasia was seen in 12 infants (38%). Hypoplasia of the corpus callosum was seen in 28 infants (88%). See [eSupplement 3](#) (available at [jaapos.org](#)).

Discussion

Numerous authors have described the neurological and ocular findings seen in children with CZS.^{4,7-11} However, this is the first study to evaluate the effect of complex ocular and neurological conditions on visual function and visual developmental milestone. After performing a comprehensive ophthalmic and neurologic assessment in a sample of infants with serological confirmation for ZIKV infection, findings indicate that many of these children are likely to have cortical/cerebral visual impairment.

Despite being originally developed to objectively evaluate visual acuity in children with normal neurodevelopment, the Teller Acuity Cards has already been successfully used for children with intellectual disabilities and cortical/cerebral visual impairment.^{13,18-21} In the current study, not only was visual acuity was tested (and found to be abnormal in 73% infants), but visual function and visual developmental milestones were also evaluated.

Nystagmus was identified in 28% of infants; strabismus, in 75%. These oculomotor conditions interfere with the development of binocular vision and stereopsis, and may indicate early visual impairment.²² In addition, refractive errors and deficient accommodation, if not corrected early, may contribute to difficulty in development of eye contact, social interaction, and overall learning. Treatment for amblyopia, glasses for magnification (low vision) or poor accommodation, patching, and strabismus surgery may be indicated as part of the rehabilitation to enable the child to have better functional vision.

When evaluating visual function and visual milestones, all evaluated children presented abnormality in at least one of the visual function and visual developmental milestone tests. Although some children presented with milder visual dysfunctions, 1/4 of the babies could not make eye contact, 1/5 could not recognize a face, and more than 1/2 presented with no social smile. These developmental skills are often affected in children with low contrast sensitivity because a facial expression involves low contrast and movement; and the inability to perform these functions interferes with the familial bonding, socialization, and communication.^{21,22}

Surprisingly, the present study revealed that, regardless of fundus involvement, all infants presented with visual impairment, suggesting that the visual impairment is most likely related to the extensive damage to the central nervous system (CNS). This hypothesis is supported by a number of mice model studies showing that ZIKV severely attacks neural progenitor cells causing cell death and restricting neurodevelopment.²³⁻²⁶ In addition, a recent study by Van der Pol and colleagues²⁶ identified ZIKV infection in the retinal tissue of mice as well as in the CNS visual system

tract, including the optic chiasm, suprachiasmatic nucleus, lateral geniculate nucleus, and/or the superior colliculus. These findings reinforces our supposition that brain damage is the main etiology for visual impairment in CZS.

In fact, all infants of this study presented with severe neurological findings. Some presented with a phenotype similar to fetal brain disruption sequence, including microcephaly, abnormal brain development, and severe neurologic impairment.⁴ However, additional neurological findings identified in CZS, such as limb hypertonias with pyramidal and extrapyramidal muscle tone involvement, and exacerbated primitive reflexes, are not consistent with brain disruption sequence. Seizure disorders were also frequent in this study cohort, corroborating the findings of Alves and colleagues,²⁷ who detected a high incidence of seizures before 6 months of age in a series of 106 infants with CZS.

The neuroimaging abnormalities identified in the current study were similar to those of previous studies.^{4,6,28} Brain calcifications were evident in radiological examinations in 97% of infants. Although case 3 did not present with brain calcifications, the child tested positive for ZIKV infection in the cerebrospinal fluid and presented with cortical abnormalities, probable cortical/cerebral visual impairment, strabismus (esotropia), and nystagmus.

Of note, 3 infants (9%) did not present with microcephaly at birth, only developing this finding later, as described by van der Linden and colleagues.²⁸ Of these infants, case 14, previously reported by Ventura and colleagues,²⁹ was the only one to present with a macular chorioretinal scar. Nevertheless, all infants presented with abnormal visual function and visual developmental milestones.

Our study emphasizes the need for healthcare professionals to recognize that infants exposed to ZIKV in utero may present with abnormal visual function, regardless of the head circumference at birth and retinal or optic nerve conditions.

Strengths of this study include having the same experienced pediatric ophthalmologists performing TAC, visual function, and visual developmental milestone tests to evaluate the visual impairment in these infants. Limitations include the relatively small sample size, and the presence of motor impairment in certain cases, which may have limited the child's response for visual function testing, particularly when testing the visual developmental milestones. In addition, because most children presented with significant neurologic irritability and 69% had seizure disorders requiring medication, this may have interfered with the measurement of visual acuity and functions. Fatigue factor in the second eye examined for the visual acuity may have contributed to the left eye exhibiting worse visual acuity, because the first eye examined was always the right eye.

In conclusion, given that all children presented with neurological and neuroimaging abnormalities, that less than half presented with retinal and/or optic nerve findings, and that all presented with visual impairment, we believe that cortical/cerebral visual impairment is the main cause of visual impairment in children with CZS.

This study also provides baseline information that can be useful in planning early intervention programs for visual habilitation.

References

- Petersen LR, Jamieson DJ, Powers AM, Honein MA. Zika virus. *N Engl J Med* 2016;374:1552-63.
- World Health Organization (WHO). Zika situation report. Available at: <http://www.who.int/emergencies/zika-virus/situation-report/3-november-2016/en/>. Accessed November 5, 2016.
- Moore CA, Staples JE, Dobyns WB, et al. Characterizing the pattern of anomalies in congenital Zika syndrome for pediatric clinicians. *JAMA Pediatr* 2017;171:288-95.
- De Fatima Vasco Aragao M, van der Linden V, Brainer-Lima AM, et al. Clinical features and neuroimaging (CT and MRI) findings in presumed Zika virus related congenital infection and microcephaly: retrospective case series study. *BMJ* 2016;353:i1901.
- Leal MC, Muniz LF, Ferreira TS, et al. Hearing loss in infants with microcephaly and evidence of congenital Zika infection—Brazil, November 2015–May 2016. *MMWR Morb Mortal Wkly Rep* 2016; 65:917-19.
- Van der Linden V, Rolim Filho EL, Lins OG, et al. Congenital Zika syndrome with arthrogryposis: retrospective series study. *BMJ* 2016; 354:i3899.
- Ventura CV, Maia M, Bravo-Filho V, Góis AL, Belfort R Jr. Zika virus in Brazil and macular atrophy in a child with microcephaly. *Lancet* 2016;387(10015):228.
- Ventura CV, Maia M, Ventura BV, et al. Ophthalmological findings in infants with microcephaly and presumable intra-uterus Zika virus infection. *Arq Bras Oftalmol* 2016;79:1-3.
- Ventura CV, Maia M, Travassos SB, et al. Risk factors associated with the ophthalmoscopic findings identified in infants with presumed Zika virus congenital infection. *JAMA Ophthalmol* 2016;134:912-18.
- de Paula Freitas B, de Oliveira Dias JR, Prazeres J, et al. Ocular findings in infants with microcephaly associated with presumed Zika virus congenital infection in Salvador, Brazil. *JAMA Ophthalmol* 2016;134: 529-35.
- Miranda HA 2nd, Costa MC, Frazão MA, Simão N, Franchischini S, Moshfeghi DM. Expanded spectrum of congenital ocular findings in microcephaly with presumed Zika infection. *Ophthalmology* 2016; 123:1788-94.
- Teller DY, Dobson V, Mayer DL. Reference and Instruction Manual Teller Acuity Cards™ II TAC II. Available at: http://eiiwebassets.s3.amazonaws.com/s/stereoptical/pdf/other-manuals/TAC_II_manual.pdf; 2005. Accessed March 10, 2017.
- Salomão SR, Ventura DF. Large sample population age norms for visual acuities obtained with Vistech-Teller Acuity Cards. *Invest Ophthalmol Vis Sci* 1995;36:657-70.
- Chen D, Calvello G, Friedman CT. Parents and Their Infants with Visual Impairments (PAIVI). 2nd Edition Kit. Louisville, Kentucky: American Printing House for the Blind; 2015.
- Hyvärinen L, Walther R, Jacob N, Lawrence L, Nottingham Chaplin PK. Delayed visual development: development of vision and visual delays. January 27, 2016. <http://www.aao.org/pediatric-center-detail/delayed-visual-development-development-of-vision-v>. Accessed on February 20, 2017.
- World Health Organization (WHO). Screening, assessment and management of neonates and infants with complications associated with Zika virus exposure in utero: Interim guidance update. Revised June 2016. Washington, DC: World Health Organization (WHO), <http://www.who.int/csr/resources/publications/zika/assessment-infants/en/>; 2016. Last Update August 30 2016. Accessed November 8, 2016.
- Villar J, Cheikh Ismail L, Victora CG, et al., International Fetal and Newborn Growth Consortium for the 21st Century (INTERGROWTH-21st). International standards for newborn weight, length, and head circumference by gestational age and sex: the Newborn Cross-Sectional Study of the INTERGROWTH-21st Project. *Lancet* 2014;384(9946):857-68.
- Mayer DL, Fulton AB, Sossen PL. Preferential looking acuity of pediatric patients with developmental disabilities. *Behav Brain Res* 1983; 10:189-97.
- Birch EE, Bane MC. Forced-choice preferential looking acuity of children with cortical visual impairment. *Dev Med Child Neurol* 1991;33:722-9.
- O'Dell CD, Harshaw K, Boothe RG. Vision screening of individuals with severe or profound mental retardation. *Ment Retard* 1993;31: 154-60.
- Hertz BG, Rosenberg J. Effect of mental retardation and motor disability on testing with visual acuity cards. *Dev Med Child Neurol* 1992;34:115-22.
- Droste PJ, Archer SM, Helveston EM. Measurement of low vision in children and infants. *Ophthalmol* 1991;98:1513-18.
- Cugola FR, Fernandes IR, Russo FB, et al. The Brazilian Zika virus strain causes birth defects in experimental models. *Nature* 2016; 534:267-71.
- Li C, Xu D, Ye Q, et al. Zika virus disrupts neural progenitor development and leads to microcephaly in mice. *Cell Stem Cell* 2016;19: 120-26.
- Wu K, Zuo G, Li X, et al. Vertical transmission of Zika virus targeting the radial glial cells affects cortex development of offspring mice. *Cell Res* 2016;26:645-54.
- Van der Pol AN, Mao G, Yang Y, Ornaghi S, Davis JN. Zika virus targeting in the developing brain. *J Neurosci* 2017;37:2161-75.
- Alves LV, Souza Cruz DD, van der Linden A, et al. Epileptic seizures in children with congenital Zika virus syndrome. *Rev Bras Saúde Matern Infant* 2016;16:S27-31.
- Van der Linden V, Pessoa A, Dobyns W, et al. Description of 13 infants born during October 2015–January 2016 with Congenital Zika virus infection without microcephaly at birth - Brazil. *MMWR Morb Mortal Wkly Rep* 2016;65:1343-8.
- Ventura CV, Maia M, Dias N, Ventura LO, Belfort R Jr. Zika: neurological and ocular findings in infant without microcephaly. *Lancet* 2016;387:2502.

eTable 1. Monocular and binocular VA, ocular motility, dynamic retinoscopy, and cycloplegic refraction of children with congenital Zika syndrome

Case	Age at testing, months	Teller Acuity Cards II measured at 38 cm, cycles/cm			Interpretation of VA scores based on normative age graph			Strabismus, PD	Nystagmus	Dynamic retinoscopy, BE	Cycloplegic refraction, D		
		RE	LE	BE	RE	LE	BE				RE	LE	
1	6	9.8	9.8	9.8	Norm	Norm	Norm	No	No	Norm	PLANO	-1.25 × 180	+0.50 -1.50 × 180
2	7	0.64	0.86	0.86	Ab	Ab	Ab	ET = 50	No	UE	+1.50		+2.00
3	5	0.86	0.86	1.3	Ab	Ab	Ab	ET = 50	Yes	Norm	+1.00	-1.00 × 180	-2.50 -2.00 × 180
4	6	4.8	4.8	6.5	Norm	Norm	Norm	ET = 35	No	Norm	+1.00		+1.00
5	6	4.8	4.8	4.8	Norm	Norm	Norm	No	No	NA	-1.50	-1.50 × 180	-1.00 -1.00 × 180
6	6	2.4	3.2	NA	Ab	Ab	NA	XT = 25	Yes	NA	PLANO		PLANO -1.00 × 180
7	7	0.86	2.4	2.4	Ab	Ab	Ab	XT = 10, HT = 15	No	Ab	PLANO	-1.50.180	PLANO -2.00 × 180
8	4	2.4	2.4	2.4	Norm	Norm	Norm	No	No	UE	+3.50	-1.00 × 180	+3.00 -1.00 × 180
9	6	0.64	0.86	0.86	Ab	Ab	Ab	XT = 45	No	UE	+4.00	-1.00 × 180	+4.00 -2.00 × 180
10	6	0.86	0.86	4.8	Ab	Ab	Norm	ET = 65	Yes	Norm	+4.00	-1.50 × 180	+3.00 -1.50 × 180
11	6	1.3	1.3	1.6	Ab	Ab	Ab	ET = 40	No	NA	+3.00		+3.00
12	6	NA	NA	NA	NA	NA	NA	XT = 40	Yes	Ab	+0.50	-1.00 × 180	+0.50
13	4	1.3	1.3	3.6	Ab	Ab	Ab	No	No	NA	+1.00	-1.00 × 180	+0.50 -1.00 × 180
14	5	0.32	0.23	0.32	Ab	Ab	Ab	XT = 25	No	UE	+1.50	-0.50 × 90	+1.00
15	4	0.23	0.23	0.32	Ab	Ab	Ab	VA	Yes	UE	+3.00		+2.50
16	6	1.6	1.6	1.6	Ab	Ab	Ab	ET = 20	No	Norm	+3.00		+3.00
17	6	2.4	2.4	2.4	Ab	Ab	Ab	ET = 40	No	Ab	+3.00	-1.00.180	+2.50 -0.50.180
18	5	0	0	0	Ab	Ab	Ab	XT = 35	No	UE	+3.00		+3.00
19	5	4.8	4.8	NA	Norm	Norm	NA	No	No	Norm	+1.00		+1.00
20	7	1.6	1.6	2.4	Ab	Ab	Ab	No	No	Norm	+1.50	-1.00 × 180	+1.00 -1.50 × 180
21	6	1.3	0.23	NA	Ab	Ab	NA	ET = 65	Yes	UE	+1.50	-1.00 × 180	+0.50 -0.50 × 180
22	5	3.2	3.2	4.8	Norm	Norm	Norm	No	No	Norm	+3.25	-1.00 × 180	+3.25 -1.00 × 180
23	6	0	0	0	Ab	Ab	Ab	XT = 15	No	UE	-3.00	-2.00 × 180	-4.00 -2.00 × 90
24	4	1.3	1.6	NA	Ab	Norm	NA	No	No	Norm	+1.50	-0.50 × 180	+2.00 -0.50 × 180
25	6	NA	NA	NA	NA	NA	NA	ET = 50	Yes	UE	+2.00	-3.00 × 180	+1.50 -3.00 × 180
26	5	0	0	0.23	Ab	Ab	Ab	XT = 30	No	UE	+3.00	-1.00 × 180	+3.00 -0.50 × 180
27	6	1.3	1.3	1.6	Ab	Ab	Ab	Var	No	UE	+1.50		+2.50
28	5	1.3	1.3	2.4	Ab	Ab	Ab	Var	Yes	UE	+1.00	-0.50 × 180	+1.00 -0.50 × 180
29	7	1.3	1.6	NA	Ab	Ab	NA	ET = 35	No	Ab	+1.50		+1.50
30	6	UE	UE	0.23	Ab	Ab	Ab	XT = 25	Yes	UE	+1.50		+1.00
31	6	1.6	1.6	1.6	Ab	Ab	Ab	XT = 40	No	Ab	+2.50	-0.50 × 180	+2.50
32	6	1.3	2.4	2.4	Ab	Ab	Ab	XT = 20	No	UE	+1.00	-0.50 × 180	+1.00

Ab, abnormal; BE, both eyes; D, diopter; ET, esotropia; LE, left eye; NA, no information available; Norm, normal; PD, prism diopter; RE, right eye; UE, unable to evaluate; VA, visual acuity; Var, variable angle; XT, exotropia.

eTable 2. Visual function and visual developmental milestones evaluation of children with congenital Zika syndrome

Case	Milestones ^a								
	Human face	Hiding Heidi 5% (contrast)	Shift of gaze	2 mos	3 mos		5-6 mos		
				Eye contact	Regards hands	Social smile	Goal-directed reach	Moves to reach	Hands to midline
1	Norm	Norm	Norm	Norm	Norm	Norm	Norm	Ab	Ab
2	Norm	Ab	UE	Norm	Norm	Norm	Norm	Norm	Ab
3	Norm	Ab	Norm	Norm	Ab	Norm	Ab	Ab	Ab
4	Norm	Norm	Norm	Norm	Ab	Norm	Norm	Norm	Norm
5	Norm	Norm	Norm	Norm	Norm	Norm	Norm	Ab	Ab
6	Norm	Ab	Ab	Norm	Ab	Norm	Ab	Ab	Ab
7	Norm	Ab	Norm	Ab	Ab	Norm	Ab	Ab	Ab
8	Norm	Ab	Ab	Norm	Ab	Ab	—	—	—
9	Norm	Ab	Norm	Norm	Ab	Norm	Norm	Ab	Ab
10	Norm	Norm	Norm	Norm	Ab	Ab	Norm	Norm	Ab
11	NA	NA	NA	NA	NA	NA	NA	NA	NA
12	Norm	Ab	Ab	Ab	Ab	Ab	Ab	Ab	Ab
13	Norm	Ab	UE	Norm	Ab	Norm	—	—	—
14	Norm	Norm	Norm	Norm	Ab	Norm	Norm	Norm	Ab
15	Ab	Ab	Ab	Ab	Ab	Ab	—	—	—
16	Norm	Ab	Norm	Norm	Ab	Ab	Ab	Ab	Ab
17	Norm	Norm	UE	Norm	Ab	Ab	Ab	Ab	Ab
18	Ab	Ab	Ab	Ab	Ab	Ab	Ab	Ab	Ab
19	Norm	Norm	Norm	Norm	Norm	Norm	Norm	Norm	Ab
20	Norm	Norm	Ab	Norm	Ab	Ab	Ab	Ab	Ab
21	Norm	Norm	Norm	Norm	Ab	Ab	Ab	Ab	Ab
22	Norm	Norm	Norm	Norm	Ab	Norm	Ab	Ab	Ab
23	Norm	Ab	Norm	Norm	Ab	Ab	Ab	Ab	Ab
24	Norm	Norm	Ab	Norm	Ab	Ab	—	—	—
25	Ab	Ab	Ab	Norm	Ab	Ab	Ab	Ab	Ab
26	Ab	Ab	Ab	Ab	Ab	Ab	Ab	Ab	Ab
27	Ab	Ab	Ab	Ab	Ab	Ab	Ab	Ab	Ab
28	Norm	Ab	Ab	Ab	Ab	Norm	Ab	Ab	Ab
29	Norm	Ab	Norm	Norm	Ab	Norm	Norm	Norm	Ab
30	Ab	Ab	Ab	Norm	Ab	Ab	Ab	Ab	Ab
31	Norm	Ab	UE	Norm	Norm	Norm	Norm	Norm	Norm
32	Norm	Ab	Ab	Ab	Ab	Ab	Ab	Ab	Ab

Ab, abnormal; NA, no information available; Norm, normal; UE, unable to evaluate.

^aA dash indicates that the test was not age appropriate for the subject.

eTable 3. Fundus findings of children with congenital Zika syndrome^a

Case	Retinal findings		Optic disk findings	
	RE	LE	RE	LE
1	Hypochromic lesions	Hypochromic lesions	Normal	Normal
7	Pigment mottling	No	Normal	Normal
12	Chorioretinal scars	Chorioretinal scars	Pallor, increased disk cupping	Pallor, increased disk cupping
13	No	Pigment mottling	Normal	Normal
14	No	Chorioretinal scar	Normal	Normal
15	Two chorioretinal scars, pigment mottling, and attenuated vessels	Chorioretinal scar, pigment mottling, attenuated vessels	Hypoplasia, increased disk cupping	Hypoplasia, increased disk cupping
16	No	No	Hypoplasia	Hypoplasia
17	Chorioretinal scar	Chorioretinal scar	Normal	Normal
23	No	No	Pallor	Normal
24	No	Chorioretinal scar	Normal	Normal
25	Chorioretinal scar	Normal	Normal	Normal
27	Pigment mottling	No	Hypoplasia, increased disk cupping	Increased disk cupping
28	Chorioretinal scar, pigment mottling, straightening retinal vessels	Chorioretinal scar, pigment mottling, straightening retinal vessels	Temporal pallor	Temporal pallor
32	Pigment mottling	Pigment mottling	Normal	Normal

LE, left eye; RE, right eye.

^aOf the 32 patients, 18 (56%) did not present with ocular findings.